Volume 6, Number 1
ISSN 1086-427X

brain talk™

IRSA

International Radiosurgery Support Association

Ependymoma Patient Works Towards Recovery

"My senior year in High School, in 1998, I started having headaches more and more often. I just started taking headache medicine when I woke up," 20-year-old Jennifer recalls. "I took Excedrin, the only thing that helped my headaches was caffeine."

Jennifer's graduating class had several hundred students, and she graduated in the top 100. She attended high school in Utah where she lived with her father and brothers. After graduation, she traveled back East with her father and her beagle, Dodger.

"I found out about the headaches after she came back East," Jennifer's mother, Donna, says. "She had gained weight, and the doctor thought she might have thyroid problems. Then Jennifer mentioned that she had numbness around her upper cheek, so the doctor scheduled an MRI."

The MRI showed that Jennifer had an ependymoma. [Ependymomas arise from the ependymal cells that line the ventricles of the brain. They are more common in children and can spread through the spinal fluid, and are malignant.] "They called my Mom into the room and told us both about the tumor," she says. "It was scary."

Jennifer had open-skull surgery for the ependymoma. "I had a scar from ear to ear," she says.

"Jennifer's short-term memory was gone the day after the craniotomy," her mother says. "Immediately after the surgery, she developed diabetes insipidus and her thyroid stopped functioning. Now, she is insulin-dependent and needs to take a small dose of steroid, too."

"There were tumor cells in her spinal fluid," Donna says. "But radiation and Gamma Knife took care of the cells and the residual tumor."

"Beginning in September of 1998, she had 20 rounds of radiation - five days a week for four weeks," Donna says. The next month, Jennifer had Gamma Knife radiosurgery at Yale Gamma Knife Center, performed by Dr. de Lotbinière.

"She spent the month of November at Gaylord Hospital," recalls Donna. "Gaylord is a rehab hospital which has a section for people with brain injuries. She learned independent living skills there."

In December of 1998, Jennifer began chemotherapy. "She got sick and we had to stop for a while," Donna states. "We began again in March of 1999. In April, she was admitted for five days to receive a combination of VP-60 and IFOS-PHA-MIDE. But after just a quarter of a dose, she went unconscious and stopped breathing. In extremely rare cases, this reaction can happen with this type of chemotherapy."

"After this, we didn't go through the full cycle of chemo," her mother says. "We just stopped, and she hasn't had any more."

After the chemotherapy, "I lost all my hair," Jennifer says. "It was past my shoulders. I miss it. But it's starting to thicken up now."

Jennifer says she used to get an MRI every month, and then the schedule changed to every couple of months.

Three rotating health aides stay with Jennifer during the day. "We've become really good friends," she says. "We go out bowling or to the movies. I like to bowl."

"Dr. Pietski - we call him Dr. P. - comes every Friday," Jennifer says. "He does a lot of brain games with me - a lot of memory stuff. He's really helped me."

"Her short-term memory has returned some," Donna says.

"I do a lot of puzzles and word searches, and write letters to people," Jennifer states. "It helps me keep my mind going."

"In the beginning, I used to forget left and right," she says. "But I've gotten so much better, you wouldn't believe it. At least that's what they tell me. I feel it too. The body has an amazing ability to heal itself."

Stereotactic Radiosurgery Review

Ask the Doc.....2
Before & After Scans.....5
Fast Facts.....7
Neurosurgical Radiosurgery.....3
Patient Stories.....1,7,9,10
Understanding Radiosurgery.....8

Stereotactic Radiosurgery

Stereotactic radiosurgery is not surgery. The skull is never opened. Radiosurgery involves the use of precisely directed single fractions of radiation to create lesions within the brain or to treat tumors or vascular malformations with minimal damage to surrounding structures or tissues.

This works by delivering a relatively high dose of radiation in one session to the target with scalpel-like precision. The dose is designed to injure or kill the cells or their supporting blood vessels, while minimizing its effect on surrounding healthy tissue. The radiation distorts the cells' DNA, causing them to lose the ability to replicate themselves. The safety and clinical effectiveness of this technique has been established since 1968 in over 170,000 treated individuals.

The benefits include: No risks of infection or anesthesia reactions; virtually no pain; reduced costs; and an immediate return to normal activities.

Radiosurgery may or may not be appropriate for your condition. It may be used as the primary treatment or recommended in addition to other treatments you may need. Only a treating neurosurgeon can make the evaluation as to whether you can be treated. Some of the most common indications for treatment today are:

- Arteriovenous/vascular malformations
- Meningiomas
- Acoustic neuromas
- Pituitary and pineal tumors
- Metastatic tumors
- Glial and astrocytoma tumors
- All other malignant & benign tumors
- Trigeminal neuralgia
- Parkinson's tremors/rigidity
- Functional disorders

Disclaimer

All technical information regarding any technology published by IRSA, in this publication or elsewhere, has been provided by the manufacturer of the equipment. The publisher does not warrant any instrument or equipment nor make any representations concerning its fitness for use in any particular instance nor any other warranties whatsoever.

Words You May Hear

CentiGray: A unit of measurement describing the amount of energy absorbed by the body. One hundred centiGray (cGy) equals one Gray.

Conformal: Shapes in three dimensions to the shape of the tumor.

FSR or SRT: Fractionated stereotactic radiotherapy; high dose radiation treatments received over a number of sessions.

Gray: A unit of measurement describing the amount of energy absorbed by the body. One Gray equals 100 cGy.

IMRT: Intensity modulated radiation therapy. The intensity of the radiation can be changed during treatment to spare adjoining normal tissue and increase the dose to the tumor.

MRA: Magnetic resonance angiography. A method of imaging vascular structures and internal anatomy without injection of contrast media or radiation exposure.

Radioresistant: Resistant to radiation treatments.

Radiosensitive: Responsive to radiation treatments.

Radiosurgery: High-dose radiation that creates a surgical strike within a tumor or nerve usually given in one-session.

SRS: Stereotactic radiosurgery, a one-session treatment with high dose radiation within the brain only.

Stereotactic: Precise positioning in three-dimensional space.

XRT: Conventional external beam radiation therapy; small amounts of radiation therapy given over an area to eliminate stray cells and future growth.

Q&A Ask the DOC

Q: Do the "pins" on the head frame go through my skull?
A: The four pins used to secure the frame onto the head penetrate only a small amount into the outer part of the skull. It would be extremely difficult to penetrate a normal adult skull with the pins. The skull of a child or infant or a skull that had previous craniotomy defects or fractures might be easier to penetrate. Report any previous operations or head trauma to your neurosurgeon. After the placement of the frame most patients state it is not painful only annoying. The application of this type of frame in radiosurgery provides the most precisely targeted treatment over all other types of immobilization devices.

Q: Please explain more about what radiosurgery does to tumor cells. I read it distorts the DNA so cells do not know how to multiply, yet my tumor has grown.
A: In addition to distorting DNA, radiosurgery can damage the enzyme systems of tumor cells, which makes it harder for them to recover from injury. Damaged tumor cells can swell up. When tumors are treated with one-session radiosurgery, the dose of radiation is distributed in a manner that protects adjacent vital structures. Typically, the dosage is more than enough to produce the desired effect on tumor cells, but there remains the possibility that some tumor cells may escape total injury and continue to grow.

With the damage to the cells from radiation, the cells generally lose their ability to process fluid and thus may take on water. This may be shown as an "enhancement" on a scan or may cause some temporary side effects such as headaches or visual problems depending on the location of the tumor. This condition is temporary and can be treated with medication until the swelling subsides.

Have a question? Send it to: "Ask the Doc," IRSA, P.O. Box 60950, Harrisburg, PA 17106-0950 USA or e-mail it to: intouch@irsa.org.

Neurosurgical Radiosurgery: An Overview

An increasing number of patients have been considered for stereotactic radiosurgery over the last 13 years. An ongoing scientific analysis of results led to refinements in techniques and results continue to improve.

Stereotactic radiosurgery can play an important role in the management of vascular malformations, brain tumors and carefully selected chronic pain and movement disorders. Radiosurgery is truly a "no access" technique, but it is not risk-free. An appreciation of short- and long-term outcomes is necessary to gain the best results for patients who choose this procedure as an addition or alternative to other therapies.

This article represents the partial results of treating over 4,200 patients over a period of almost 13 years, with Gamma Knife radiosurgery, at the University of Pittsburgh. The Gamma Knife is a neurosurgical instrument utilized by neurosurgeons in a one-session surgical strike. Presently, two Gamma Knife units are used at our center. In this review, we address the current status of radiosurgery for several major treatment indications.

Neurosurgical stereotactic radiosurgery is not intensity modulated radiation therapy (IMRT) or stereotactic fractionated irradiation (SRT). Those procedures incorporate image-guidance to improve upon conventional radiation therapy. They do not provide the single-session biological effect of neurosurgical radiosurgery nor the exquisite precision necessary to manage many brain disorders.

Stereotactic radiosurgery achieves closed-skull destruction of a defined intracranial target through the precise focus of ionizing irradiation. Radiosurgery is one of several "minimally invasive" techniques for brain disorders and has received great interest as an alternative to either conventional surgical resection or fractionated radiation therapy. Over the last 15 years, the increased use of stereotactic guiding techniques, improved high-resolution neuroimaging and a trend toward less invasive neurosurgery has facilitated installation of Gamma Knife units and modified linear accelerators at many centers.

Arteriovenous Malformations

Stereotactic radiosurgery has had a wide application in the management of cerebral arteriovenous malformations (AVMs). This technique has been used in patients with small to medium sized AVMs in all brain locations, but perhaps its greatest role is in the management of AVMs in critical brain locations. The roles of microsurgical resection, embolization and radiosurgery are now defined more clearly so that physicians and patients can choose appropriate strategies more specifically. The goal of radiosurgery is complete obliteration of the AVM nidus achieved through proliferation of endothelial cells lining the vessel wall, its progressive thickening and eventual blood vessel closure. It usually takes one to three years before obliteration occurs.

We have managed over 810 patients with arteriovenous malformations of the brain. An additional 84 patients had radiosurgery for cavernous malformations. All patients selected for radiosurgery had a well-defined vascular malformation as seen on preoperative high-resolution angiography or MRI scan. Patients ranged in age from 2 to 82 years old; the average age was 36.

Successful AVM obliteration is dependent upon good target definition, the radiosurgical dose administered and the AVM's volume. Problems with target definition are the single greatest reason for failure to achieve obliteration. Multiple, three-dimensional imaging including MRI, MRA and angiography is crucial to obtain the best result. For the smallest AVMs (less than 1.3 ml), 90% of patients had complete obliteration and 98% had obliteration of the target. The obliteration rate lessens for larger AVMs but remains above 70%. Again, the radiosurgical dose must be appropriately tailored to the AVM margin as defined by multimodality imaging.

Immediate post-radiosurgery complications are rare. Six percent of patients had a new neurologic deficit after radiosurgery that in most cases was temporary.

Staged procedures (usually two or three procedures spaced by 3 to 6 months) for selected large AVMs is a new therapy for surgically untreatable AVMs. Such a program is under evaluation at our center, and 17 patients have now been treated.

Acoustic Neuromas

We have managed 651 patients with acoustic neuromas as an alternative to microsurgical resection according to one or more of the following criteria: advanced patient age, poor medical condition for surgery, recurrent or residual tumor after prior surgery, neurofibromatosis type II (a disorder involving swellings that grow from nerves) or patient preference.

Our review of patients with acoustic tumors with 5 to 10 years follow-up (162 patients managed between 1987 and 1992) was compared to our published review of 190 patients managed between 1992 and 1997. We found that the clinical tumor control rate (no requirement for surgical intervention) for the first group was 98%, and 97% for the second.

Since 1987, there have been significant modifications in the technique of acoustic tumor radiosurgery including a change from CT to MRI based planning, improved computer workstations, the use of more isocenters of radiation, the use of smaller irradiation beams and a reduction in the radiation dose. Since the institution of these techniques beginning in 1991, there has been a significant reduction in the morbidity of radiosurgery. Since 1992, the risk for a delayed, mild facial weakness is below 1% and for facial numbness, below 3%. A survey of these patients with at least five-year follow-up found that 97% believed radiosurgery was a good treatment for their acoustic neuromas.

Radiosurgery has been shown to be a cost-effective alternative to microsurgery for acoustic neuroma patients in a recent outcome analysis.

Meningiomas

Stereotactic radiosurgery is applicable for patients with intracranial meningiomas because these tumors are usually well defined and rarely invade the brain unless malignant. The steep radiation fall-off can be directly targeted to the tumor margin. Meningiomas are well visualized on imaging studies and can be recognized even when small. As many tumors exist at the skull base where a total resection is often not feasible, ra-

Continued on page 4

Contributing Authors

Dr. Kondziolka

Dr. Flickinger

Dr. Lunsford

Neurosurgical Radiosurgery

Continued from page 3

diosurgery can be used as a second stage approach after prior microsurgical resection to treat residual tumor in critical brain locations such as the cavernous sinus. Delayed tumor recurrence after surgery, surgical morbidity and surgical mortality, especially in the elderly, increasingly has led to consideration of radiosurgery for primary or adjuvant treatment of selected meningiomas.

We used radiosurgery in 584 patients with meningiomas. Long-term prevention of tumor growth remains above 90% for these patients. Five percent have had imaging-defined tumor enlargement after radiosurgery. Two patients treated before 1990 had delayed visual symptoms after radiosurgery: one had a temporary decrease in visual acuity that returned to normal and another a delayed persistent hemianopia (visual field loss). Since a rigid protocol restricting the dose to the optic apparatus to less than 8 Gy was begun 10 years ago, no meningioma patient has had a delayed visual deficit. Many believe that aggressive skull base surgery is no longer required for patients with small or medium sized tumors and that radiosurgery alone or resection plus radiosurgery (for larger tumors) is a better choice.

Brain Metastases

Radiosurgery perhaps has had its greatest recent role in the management of patients with metastatic brain tumors. Local control provided by radiosurgery for the management of tumors in any brain location exceeds 85% on average. Patients with four or fewer tumors are usually good candidates for radiosurgery. As a minimally invasive procedure that provides excellent local control, relief of symptoms, and avoids open craniotomy, radiosurgery is an attractive and cost-effective treatment for both patients and physicians managing these problems.

To date, the results after radiosurgery plus whole-brain radiation therapy appear equal to surgical resection plus whole-brain radiation. Radiosurgery is effective for tumors traditionally considered "radiation-resistant," including melanoma and renal cell carcinoma. To date, we have managed 788 patients with brain metastases.

Radiosurgery has been shown to be a cost-effective management strategy compared to either surgical resection or whole brain radiotherapy for patients with solitary brain metastases.

Malignant Gliomas

Radiosurgery has been used to provide a radiation boost in the management of patients with malignant glial tumors, in addition to a regimen of fractionated radiation therapy. Increasing interest in interstitial irradiation (brachytherapy) through the 1980s was followed by interest in the use of radiosurgery as an alternative method of providing a local radiation boost without the need for invasive catheter placement. At our center, most patients with malignant gliomas first undergo stereotactic biopsy or image-guided resection. Initial adjuvant therapy consists of fractionated radiation therapy and sometimes chemotherapy. Radiosurgery is used as an additional treatment for patients with contrast-enhancing masses less than 3.5 cm in average diameter.

We believe that radiosurgery plays an important role in the multi-modality management of patients with malignant glial tumors. In our experience, median survival after radiosurgery (not diagnosis) was 16 months for patients with glioblastoma and 21 months for patients with anaplastic astrocytoma.

When compared to standard radiation therapy survivals reported by the Radiation Therapy Oncology Group, significant benefits were obtained after radiosurgery.

Pituitary Tumors

An evaluation of our series of 155 patients who had stereotactic radiosurgery for pituitary tumors was performed. Two-thirds had hormone-secreting tumors. Tumor growth control was achieved in 94% of patients and 46% noted a decrease in tumor size. Most of the time, radiosurgery is performed following a partial transsphenoidal resection, or after a craniotomy. Radiosurgery should be considered a first choice if the tumor clearly involves the cavernous sinus region.

For patients with acromegaly (growth hormone secreting tumor), normalization of growth hormone levels was identified in 72% of patients and a significant reduction was identified in an additional 21%. For patients with Cushing's disease (adrenocorticotropic hormone secreting tumor), normalization of pituitary function was identified in 52% and another 14% showed a significant decrease in secretion.

New neurologic problems after radiosurgery were rare. Two patients in our early experience had visual deficits: one patient who had multiple prior surgeries and radiation therapy experienced hypothalamic deficit, and the other had new onset facial sensory loss. No patient developed additional pituitary hormone deficits after radiosurgery.

Continued on page 6

Before & After One Session Neurosurgical Radiosurgery

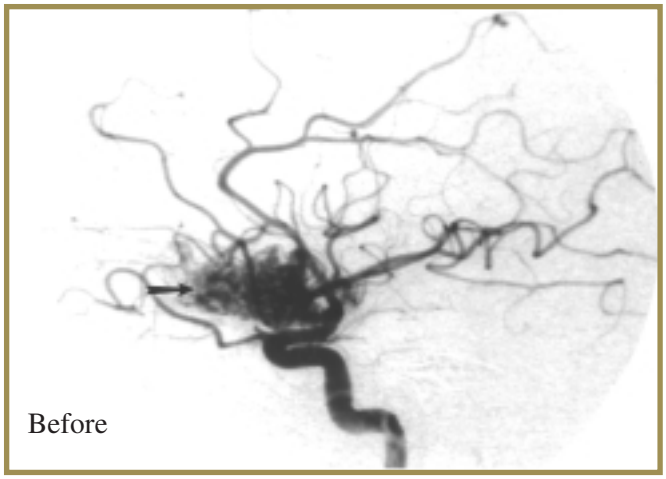

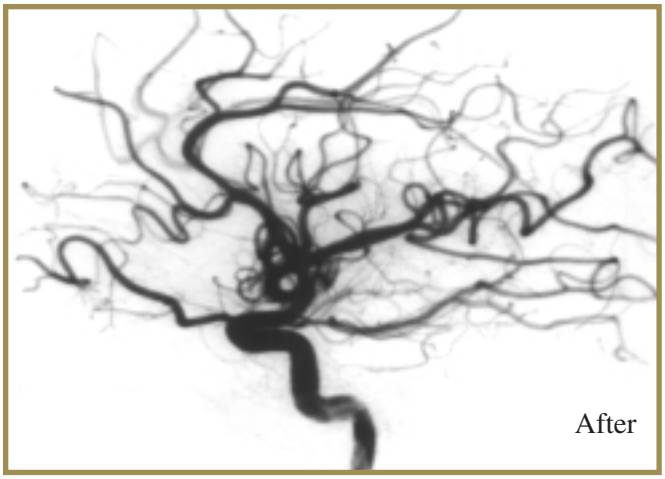

An arrow points to a large frontal AVM on an angiogram in a 34-year-old patient with a long history of seizures. The AVM has been completely obliterated 2 years later.

Before

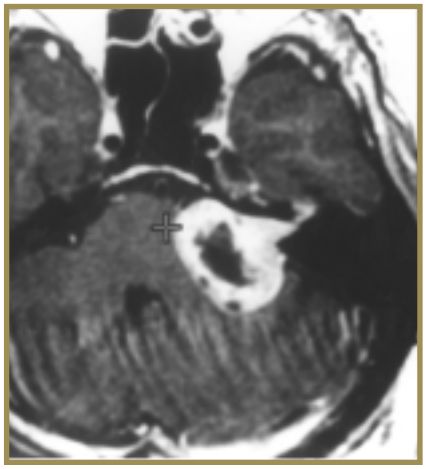

After

MRI scans show a young adult's acoustic neuroma at the time of radiosurgery (left) and three years later (right). Significant tumor regression was noticed with no new neurological deficits.

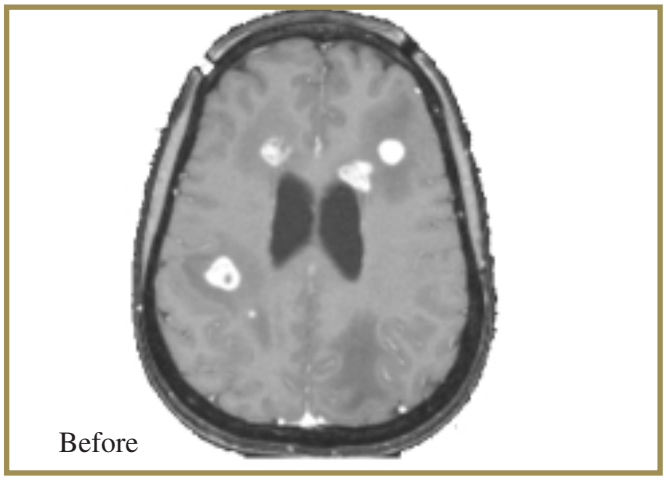

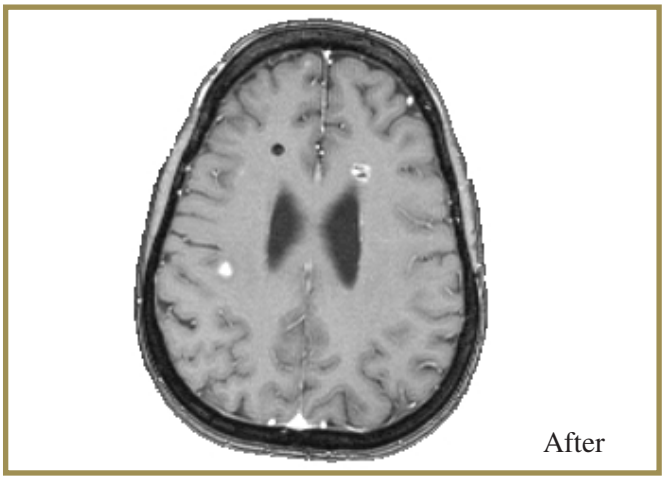

Multiple metastatic brain tumors (white spots) before and 4 months after neurosurgical radiosurgery.

Neurosurgical Radiosurgery

Continued from page 4

Other Benign Tumors

Radiosurgery has been used to manage patients with an array of other benign tumors that include craniopharyngiomas, hemangioblastomas, trigeminal nerve and jugular foramen schwannomas, choroid plexus papillomas, and neurocytomas. Tumor volume and location are important factors for the selection of radiosurgery over other therapeutic alternatives. Although these tumors are less common, there is an increasing experience in the use of radiosurgery, usually after a biopsy or resection has confirmed the diagnosis. The response rate to radiosurgery appears high, as for other benign tumors.

Other Malignant Tumors

Malignant tumors of the skull base can be treated effectively with radiosurgery. Such tumors include chordomas, chondrosarcomas, nasopharyngeal carcinomas, or other adenocarcinomas or squamous cell carcinomas from regional structures. We use radiosurgery for residual or recurrent cancers that invade the cranial base. Because the radiation dose can be delivered in a single session and spare surrounding critical brain structures, radiosurgery has potential advantages over fractionated techniques or radiation implants for the management of malignant skull base tumors. To date, radiosurgery is often selected after other procedures or treatments have failed. Complications from treatment are unusual. Other malignant tumors of the brain include germinomas and non-germinomatous germ cell tumors, and CNS lymphomas. Germinoma, a radiosensitive tumor, appears to respond quickly and dramatically to radiosurgery.

Further evaluation will be necessary in a larger series of patients to define the response of different tumor histologies in order to more clearly determine the role of radiosurgery in contrast to other surgical techniques or radiation delivery methods.

Trigeminal Neuralgia

One initial use of stereotactic radiosurgery was for lesion generation in functional neurosurgical procedures. Increasingly, Gamma Knife radiosurgery is used to treat trigeminal neuralgia (TN). We have treated 383 TN patients to date. Radiosurgery was performed sparingly for this indication until recently, when high resolution imaging of the trigeminal nerve provided excellent definition of the target. At present, we use a maximum radiosurgical dose of 80 Gy for most patients. This provides a significant rate of pain relief, with an approximate 10% chance of mild facial numbness.

Initial experience has mainly been in patients with recurrent pain after prior surgery. Approximately two-thirds of patients became pain-free off medication and another 20% obtained significant benefit. Trigeminal neuralgia radiosurgery requires the use of small collimators (4 mm) and highly precise targeting. At this time, only Gamma Knife techniques have been validated for trigeminal neuralgia radiosurgery.

Movement Disorders and Tremor

Since the Gamma Knife can be used to create a focal radiosurgery brain lesion, it can be used to perform thalamotomy, a procedure used to treat tremor. We consider this for patients who have medical contraindications to open thalamotomy or to deep brain stimulation. We have performed 44 radiosurgical thalamotomies for tremor (Parkinson's disease, essential tremor, and multiple sclerosis tremor). The majority of patients note significant tremor relief 1 to 3 months following radiosurgery. Rarely, hand numbness or weakness can develop in

Continued on page 11

Commentary: Neurosurgical Radiosurgery

When Lars Leksell conceived of radiosurgery as "a technique for the non-invasive destruction of intracranial tissues or lesions" fifty years ago, he could not have imagined the central role this technique would occupy in the armamentarium of today's modern neurosurgical practice. With over 100,000 patients treated with the Gamma Knife radiosurgery to date and many others treated with alternative tools, stereotactic radiosurgery has now firmly entered the mainstream of neurosurgery and is being given an increasingly important place in radiation oncology.

The group at the University of Pittsburgh, Dr. Dade Lunsford and Dr. Doug Kondziolka, has been instrumental in the establishment of this technique as a viable alternative to open surgery, having produced a number of papers analyzing the long-term outcome of patients undergoing Gamma Knife neurosurgical stereotactic radiosurgery for a variety of conditions. This paper represents a summary of their enormous experience gained over 13 years of treating patients with this technique. The results speak for themselves. Not surprisingly, many patients wish to be considered for treatment using stereotactic radiosurgery in the hope of avoiding invasive and (at times) debilitating surgery. The result has been that many neurosurgeons who have summarily dismissed stereotactic radiosurgery as having no place in the treatment of patients with benign brain tumors or arteriovenous malformations have been forced to reexamine their own results in light of those obtained with less invasive techniques. Radical and aggressive surgery has now given way to "minimally invasive" surgery resulting in shorter hospitalization times and a decrease in morbidity. Patients can now choose between a variety of techniques rather than being presented with only one approach.

It is nevertheless important to realize that not all conditions can be treated with stereotactic radiosurgery and that open surgery will always have a place in the treatment of many intracranial disorders. Patients need to understand the limitations of any particular technique and should be wary of institutions that go to no end to promote and advertise their particular point of view. As indicated by the authors, radiosurgery can lead to excellent outcomes when properly performed for the right indications, but equally disastrous outcomes can occur when this technique is used for the wrong indications or when it is poorly performed. Perhaps we need most of all to remember Leksell's words: "A fool with a tool is still a fool."

Alain C. de Lotbinière

Alain C. de Lotbinière, MD, FRCSC, FACS, Neurosurgeon
Medical Director of Yale Haven Gamma Knife Center, Associate Professor of Neurological Surgery
Yale University School of Medicine
333 Cedar Street, New Haven, CT 06510 USA
Ph: 203-785-2808, Fax: 203-785-2098, E-Mail: alain.delotbiniere@yale.edu

Metastatic Testicular Cancer Invaded Entire Body

"In December 1998, my primary doctor diagnosed me with 'testicular cancer from head to toe,' says Carl.

Carl's first symptoms were in his lungs. "I had tennis lessons in the fall of 1998," he says. "I'd hit three or four balls, and have to sit down. I could not breathe on the tennis court."

"I just thought I had the flu," he says. "I never hurt from the cancer."

"I was immediately whisked to Houston to M.D. Anderson Cancer Center, where I saw physicians in the Department of Genitourinary Medical Oncology," Carl recalls. "The first time they took my blood, they said my tumor markers were really high, and that they'd never seen them that high. They said, 'Go back to the hotel - we'll call you in the morning.'"

"I was told that if I was not treated immediately, I had two months to live," Carl remembers. "I was given a round of chemo, which lasted about four days."

Carl doesn't sleep well in the hospital. "I never got used to needles," he says. "I couldn't go to sleep at night because I was always afraid that someone would stick a needle in me during my sleep."

"Houston was so hard on me - intimidating, I think," he relates. "I really did not know when it was going to end."

"While I was getting chemo at M.D. Anderson, I called the main number at 3:30 am," Carl recalls. "The lady [at the desk] said the Lord's Prayer with me."

After the chemotherapy, Carl had a craniotomy to remove brain metastases in December 1998. "After the initial operation, I had a big bald spot on the back of my head, but I couldn't see it," Carl relates. "I went for a haircut while at M.D. Anderson and was surprised when they shaved all my hair off."

"In early 1999, I was introduced to my oncologist, Allison M. Garner, M.D., at Southwest Texas Methodist Hospital in San Antonio, where I had 13 rounds of heavy chemo and two testicular surgeries in between," Carl says. "I lost 60 pounds. I was throwing up gallons. Thankfully I was a little overweight. But I wouldn't recommend this diet."

"The first time people came to see me in the hospital, they really didn't know what was going on," he says. "Next time,

Carl

there's a look of pure horror on their faces. And I wished at that time that I would have been a great painter, so I could have captured their expressions."

"In early 2000, my tumor markers were still a little high, and they gave me another of my countless MRIs and found a small amount of bleeding in two spots in my brain. I thought, 'not more surgery.'"

"Dr. Arnold B. Vardiman with Southwest Texas Methodist Hospital in San Antonio explained the Gamma Knife procedure and treated me in January of 2000," Carl reports. "I went in at 6 am and was home at noon. It cleared everything up without any extra surgery."

"In February 2000, the Gamma Knife was followed up by 20 rounds of radiation to my brain," he states.

"In April of 2000, the doctors said the final stop was lung surgery," Carl recalls. He had 14 tumors in his lungs. "They were going to cut me open about a foot on each side, about two months apart," he says.

"In the last week in April, in San Antonio, we have Fiesta Week, which is a small party week," Carl states. "I asked one of my doctors and her husband to go to a garden party during Fiesta week. I think she was amazed to see me there," Carl recalls. "It was really special. She has turned into a super friend."

"I was scheduled for lung surgery on May 1, but my blood would not coagulate. Why?" Carl asks. "I had been drinking -'a fair amount' - during Fiesta week."

"Two months later I had another CT scan," Carl recalls. "I was used to these by this time. To everyone's surprise, everything had cleared up in both lungs except for a small lesion on the periphery of each lung. No one knows why - maybe prayers worked."

"I had thoracoscopic surgery on both lungs at the same time [to take out the small lesions that were left]," Carl says. "I had surgery on my lungs on Thursday and was home at noon on Friday. Both lesions were benign scar tissue."

"Meanwhile, I've started a new business, a grain store, where I sell deer corn and black-oiled sunflower seeds for bird-feeding," Carl says.

"My feet are very slowly getting back to normal," he reports. Because of the chemotherapy, Carl suffers from neuropathy in his feet. "My movement is still a little awkward," he says.

Now, Carl says, "I feel good."

Carl enjoys playing tennis, and was rated 4.5 before the cancer. Now he is rated 4.0. Because of the neuropathy in his feet, playing tennis has been difficult.

"When I was taking walks again on the golf course in 2000, the golf course takes on another meaning," Carl relates. "It was just so pretty - the ducks, the green grass."

"You can't give up - things look bad at times, but you can't give up," Carl says. "You know I prayed to God so many times. It was scary. But you can't give up. You've got to keep going."

Radiosurgery Fast Facts

- One-day stay or outpatient treatment.
- No risk of bleeding or infection.
- General anesthesia is not necessary.
- Mostly painless.
- Immediate return to normal activities.
- No physical therapy or rehabilitation.
- Covered by insurance and Medicare.
- Used as primary or secondary treatment.
- Can be retreated if needed.
- Over 10,000 one-session surgical treatments annually (USA).
- Over 10,000 multi-session LINAC treatments annually (USA).
- Can be used after whole brain radiation.

Understanding Stereotactic Radiosurgery

Radiosurgery Has Surgical Effect on Target Area

Stereotactic radiosurgery is a way of treating brain disorders with a precise delivery of a single high dose of radiation in a one-day session. Treatment involves the use of focused radiation beams delivered to a specific area of the brain to treat abnormalities, tumors or other functional disorders. Body stereotactic radiosurgery does not exist because there is no way to immobilize the body to treat a tumor in one session the way the head can be secured. Fractionated stereotactic radiation treatments -- which are received over a period of days or weeks -- may be administered in the body with the assistance of removable masks and frames that achieve some degree of immobilization. Stereotactic radiosurgery is limited to the head and neck, because these areas can be immobilized with skeletal fixation devices that completely restrict the head's movement, permitting the most precise and accurate treatment. Treatment without a skeletal fixation device for a one-session treatment is not recommended because of the high potential for damage to healthy brain tissue, cranial nerves (optic, hearing, etc.) and the brain stem.

Radiosurgery has such a dramatic effect in the target zone that the changes are considered "surgical." Through the use of three-dimensional computer-aided planning and the high degree of immobilization, the treatment can minimize the amount of radiation to healthy brain tissue. Stereotactic radiosurgery is routinely used for brain tumors and lesions. It may be the primary treatment, utilized when a tumor is inaccessible by surgical means, or as a boost or adjunct to other treatments with a recurring or malignant tumor. In some cases, it may be inappropriate. There are two main approaches to stereotactic radiosurgery: neurosurgical stereotactic radiosurgery, and stereotactic radiotherapy.

How Radiosurgery Works

Radiosurgery works the same as all other forms of radiation treatment. It does not remove the tumor or lesion, but distorts the DNA of the tumor cells. The cells then lose their ability to reproduce and retain fluids. Tumor reduction occurs at the rate of normal growth for a specific tumor cell. In lesions such as AVMs (a tangle of blood vessels in the brain), radiosurgery causes the blood vessels to thicken and close off. The shrinking of a tumor or closing off of a vessel occurs over a period of time. For benign tumors and vessels, this will usually be 18 months to 2 years. For malignant tumors and metastatic tumors, results may be seen as soon as a few months, as these cells are very fast-growing.

As with all radiation treatments, the cells of the irradiated tumors lose their ability to regulate fluids, and edema or swelling may occur. This does not happen in all treatments. If the swelling does cause symptoms that require abating, then a course of steroid medication is usually given to reduce the fluid within the tumor cavity.

Because all forms of radiation treatments work over time, they may be inappropriate if symptoms are severe or life-threatening. Relief of acute symptoms may drive the first treatment choice to open skull surgery or medication. In cases where cells are extremely fast-growing (with or without severe symptoms), such as in brain metastases, radiosurgery can quickly control the brain tumors to allow time to treat the primary cancer site. Medication can be given for the side effects of edema and radiation therapy may be used over a period of time to help eliminate the stray cancer cells from the brain.

Who Is Treated with Stereotactic Radiosurgery?

Stereotactic radiosurgery can be used in patients who have failed standard radiation techniques or in patients who have already received the maximum radiation dose permissible or whole brain radiation. At this time, there are no known cases of radiation-induced new tumors from stereotactic radiosurgery in 33 years of treatments. This may be attributed to the preciseness of the treatment and the sparing of healthy nerves and tissues. A patient who has had stereotactic radiosurgery for a brain tumor or condition may later have open skull surgery without problems. In many cases, if necessary, additional treatments of stereotactic radiosurgery can be performed.

Stereotactic Radiosurgery Technology

There are three basic forms of stereotactic radiosurgery represented by three different technological instruments. Each instrument operates differently, has a different source of radiation and may be more effective under different circumstances. The three are:

- Particle beam (proton)
- Cobalt^{60} based (photon)
- Linear accelerator based (photon)

The particle beam (also known as proton beam) or cyclotron is in limited use in the United States. In addition to brain tumors, it also treats body cancers in a fractionated (multi-session) manner. There is not much material available on the technology and outcomes at this time. The particle beam is extremely large and funded by public research.

Neurosurgical Stereotactic Radiosurgery

Neurosurgical radiosurgery is a one-session treatment performed by a neurosurgeon. This single-session biological effect is necessary for the management of many brain disorders. It has all the aspects of a surgical strike within the brain. Cobalt^{60} based machines are usually used with neurosurgical one-session radiosurgery. They are normally located at dedicated neuroscience centers in the United States and throughout the world. These machines provide extremely accurate targeting and precise treatment for brain cancers. They are dedicated to treating only brain tumors and dysfunctions in a one-day treatment. The most well-known machine is the Gamma Knife®. However, there are other cobalt^{60} machines.

This one-session neurosurgical radiosurgery treatment is always performed under the direction of a neurosurgeon in an operating room suite. With one-session neurosurgical radiosurgery treatment, the treatment is as exacting as working with a scapel, laser or probe.

The machine does not move during treatment, thus providing a high degree of precision within the brain. It has been available for 33 years with 33 years of substantial research and follow-up backing its treatments and outcomes. The unit today is much the same as when it was developed. The machines use multiple sources of radiation, which allows for less damage to healthy tissue and better targeting. It is estimated that over 170,000 people have received treatment with this method at this time. These machines are ideal for smaller tumors and lesions and for functional disorders of the brain.

The December 2000 supplement to The Journal of Neurosurgery was devoted entirely to neurosurgical stereotactic radiosurgery. This edition can be found on-line at **www.thejns-net.org**.

Continued on page 9

Oligodendroglioma Survivor Had Symptoms for 18 Years

Editor's note:. Karen submitted this story to us.

At fifteen, I started to occasionally feel lightheaded, have headaches and pass out for no apparent reason. The family doctor couldn't find any reason. At nineteen, the doctor thought that border line blood pressure was the problem. I was put on a no-salt diet. This was in 1979. My doctor always did neurological checks but nothing showed. The black outs, lightheadedness and headaches continued until April of 1997.

One day I had a headache so bad that I laid down most of the day. I then started to vomit. I must have looked awful, for when my husband came home we went to the hospital. The doctor at first thought that I had meningitis. I refused to have a spinal tap done until I had a CT scan done. There wasn't a fever, and I felt it was a brain tumor.

The CT scan showed a tumor [oligodendroglioma] in the left parietal brain. I was relieved. The headaches, lightheadedness and black outs all made sense. An MRI was done and surgery scheduled. Most of the tumor could be removed. We found the tumor was a very slow growing, benign tumor.

Karen & her family

The biggest problem I had over the next two years was controlling the seizures. I had one medication changed. That has helped tremendously.

Last January (2000) the MRI showed that the tumor had started to grow again. Radiation was started. When it was completed I had Gamma Knife treatment at the University Hospital, Central New York Gamma Knife Center in Syracuse, New York. I only needed one treatment. Unfortunately the MRI done in September (2000) did not show if the treatment has begun to be effective yet.

I just had a PET scan on Feb. 2, 2001. This scan showed if the tumor was alive or dead. The results of the scan were that the tumor is necrotic tissue [dead tissue]. I have waited for this day for four years.

There are lots of things I do. I enjoy a small garden, being an assistant Girl Scout leader, football and track games, baseball games, camping and boating. I walk at least one mile three to four times a week. In the winter I do have a treadmill that I use. God and my family give me all the inspiration, love and laughter that I need to stay happy and healthy.

Understanding Radiosurgery

Continued from page 8

Linear Accelerator Radiotherapy

The linear accelerator (LINAC) radiotherapy based machines are also prevalent throughout the world. One benefit of this technology is its ability to easily treat very large tumor volumes by treating over time during cell division. In general, these machines lack the ability to target as precisely as cobalt^{60} machines and are not usually used to treat functional brain disorders which require more precision. The machines are made by multiple manufacturers with common brand names such as Peacock®, X-Knife®, CyberKnife®, Novalis®, Clinac® and others. The X-Knife® is the most common machine available. These machines are not dedicated to just treatments within the brain. They can be used throughout the body as well as the head and neck.

Quite often, the unit is set up before a treatment can be given after the linear accelerator couch was used for conventional radiation therapy. In facilities where this is done, the number of treatments within the brain is usually not high on an annual basis and therefore outcomes may not be as good.

The linear accelerator based machines use one large intense radiation beam that is redirected in many "arcs" to lessen the effect on healthy tissue. However, since the linear accelerator moves during treatment, the degree of precision is less than with cobalt^{60} machines. For the treatment to be considered as radiotherapy it is commonly accepted as no more than eight sessions.

When the total course of treatments will be greater than eight the treatment is generally considered to be conventional radiation therapy. However, there is still much controversy over where radiotherapy begins and ends within the radiation community.

More common today are neurological treating centers which utilize both the cobalt^{60} and LINAC machines. The cobalt^{60} machines can be used to treat around critical brain structures and to treat the tumor bed, fast and effectively in one-session. Then the LINAC machines are used to target around the tumor in multiple sessions to stop the spread of the tumor. These are perhaps some of the best scenarios for the patient.

Linear accelerator based machines can perform radiotherapy on larger tumors and

Continued on page 12

Indications for Neurosurgical Radiosurgery

Within the next 12 months, more than 200,000 people in the USA and 10,000 people in Canada will be diagnosed with a primary or metastatic brain tumor -- and the incidence is stated to be increasing. If these rates hold true elsewhere, close to 2 million people around the world may be afflicted with brain tumors and brain disorders each year. One-session neurosurgical stereotactic radiosurgery treatments can be an effective treatment for most brain tumors and brain disorders.

Here are some additional facts and figures about brain tumors and disorders:

◆ Brain tumors are the second leading cause of cancer death in children under age 15 and in young adults up to age 34.

◆ Brain tumors are the second fastest growing cause of cancer death among those over age 65.

◆ Unlike the first and third fastest growing causes of death (lung cancer and melanoma), no behavioral change has been shown to reduce the risk of a brain tumor.

◆ Approximately 40% of all primary brain tumors are benign. But unlike most benign tumors found elsewhere in the body, benign brain tumors may recur and may result in death.

◆ Benign brain tumors may cause severe life-long side effects even after treatment, such as hormonal imbalances, vision deficiencies, loss of hearing, speech problems, balance and walking imbalances, and limb weaknesses.

◆ The cure rate for most brain tumors is significantly lower than that for most other types of cancer.

◆ Metastatic brain tumors from other primary body cancers will range from 185,000 to 370,000 this year.

◆ Metastatic brain tumors are thought to occur at more than twice the rate of primary brain tumors.

◆ About 300,000 Americans, or 1 percent are believed to be affected by brain or spinal cord arteriovenous malformations.

◆ About 40,000 people are afflicted with trigeminal neuralgia each year.

◆ A higher proportion of functional brain disorders and brain tumors occur more frequently in the aged population. The aging population will increase 20% in the next 10 years.

◆ Children who are cured of leukemia are shown to be at greater risk of develop-

Continued on page 11

Vision Problems & Headaches Signaled Rare Chordoma

Two years ago, Robert began having severe headaches. "I called them 'flash headaches,'" Robert, 50, says. "They lasted a couple of seconds. They were very, very sharp and intense, and almost made me pass out."

"I also noticed my speech was a little slurred, and there was some difference in my eyesight," he states. Robert went to a doctor, who ordered an MRI. The MRI revealed that Robert had a brain tumor.

"When I found out, I was kind of in a state of shock," Robert recalls. "I didn't know what to think. You wonder, 'What are they going to do? What are the consequences of this thing?' It's quite a shock to yourself and your family. You're going along, fat, dumb and happy, and the rug's pulled out from under you."

Robert had a 3-cm clivus chordoma. [A chordoma is a rare usually benign tumor.] "The tumor was almost equidistant in the middle of my head," he says. "It was near the main artery supplying blood to my brain."

"A local neurosurgeon recommended that I see Dr. Spetzler at Barrow Neurological Institute," Robert recalls.

About one month after diagnosis, Robert had a craniotomy at Barrow Neurological Institute at St. Joseph's Hospital and Medical Center in Phoenix, Arizona. "Dr. Spetzler did retrosigmoid surgery, where they make kind of a C-cut behind the ear," Robert says. "He pioneered this surgery, from what I understand."

"I didn't think I was ever going to be normal after the regular surgery," he says. I was kind of like a digital camera without the image stabilizer: images were jumping around. It took a while to stabilize my sight and get my senses back."

A residual tumor remained after Robert's craniotomy. In August 2000, he had Gamma Knife radiosurgery for the residual tumor, performed by Dr. Kris Smith at Barrow Neurological Institute.

Robert marveled at how quiet the Gamma Knife unit was. "When I was in the Gamma Knife, I wondered, 'Is this thing on?'" he recalls.

"The tumor is still there somewhat. The idea was to sterilize it so it won't grow," Robert says. "This type of tumor keeps growing," he explains.

"I had a follow-up MRI in December," he says. "It still looked the same as at the time of the Gamma Knife." Robert will have follow-ups every six months for the next 3 to 5 years.

A credit manager for a local Caterpillar dealer, Robert and his wife Christine, a bookkeeper, have been married 26 years. They have two children: Heather, 22, and

Robert

Robert Jr., 19. "Heather is working on a doctorate in pharmacy," Robert says. "And Robert Jr. is graduating from high school and going into computer science."

When asked about hobbies and leisure activities, Robert quips, "My wife says my hobby is being a couch potato."

"We like to watch sports," he adds. "We go to the old alma mater, the University of Montana, and watch college football."

Robert and Christine have two dogs, a chow named Bear and a miniature schnauzer named Rudy. "We named the chow 'Bear' because he's cinnamon colored, and reminded us of a cinnamon bear," Robert says.

Neurosurgical Radiosurgery

Continued from page 6

the months after the procedure. Radiosurgical pallidotomy, used to treat other symptoms of Parkinson's disease, has been performed at some centers but we favor conventional radiofrequency pallidotomy.

Areas of Research

There is current interest in the use of radiosurgery for patients with focal epilepsy. This follows the observation that brain irradiation (via radiation therapy or radiosurgery) can stop seizures in patients with brain tumors or AVMs. Patient studies from Spain, Sweden, and France, and animal studies from our center, have provided the foundation for this research. Régis and associates in Marseille, France performed selective amygdalohippocampal radiosurgery for a specific kind of epilepsy caused by mesial temporal sclerosis. A clinical trial funded by the National Institutes of Health and led by University of California at San Franciso is underway to study the effects of treatment. Study centers also include University of Pittsburgh, Yale University, Northwestern University and the University of Virginia. If focal hippocampal (or any other brain tissue) irradiation can eliminate seizures without the need for complete tissue destruction, then radiosurgery may become an important therapy for patients with intractable epilepsy.

The Cyberknife system (Accuray Inc., Stanford, CA) uses camera and X-ray information to track head or body position during irradiation. This device appears to have advantages for extracranial radiosurgery of the spine and other organ systems. We are currently evaluating it in this setting, particularly for the treatment of cancer.

Fractionated stereotactic irradiation has been used by some groups to treat benign tumors in critical locations. Most groups began programs when the results found after linear accelerator radiosurgery were not acceptable. Fractionation allowed a reduction in the biologic effect of radiation to surrounding normal tissue. We think that this approach is of value when the brain lesion encompasses normal cranial nerves or brain. It should not be a replacement for conformal radiosurgery which provides more effective treatment to the tumor or vascular malformation.

Summary

Stereotactic radiosurgery has revolutionized brain surgery. By providing effective and safe treatment for patients, with long-term justification of results, many can confidently choose radiosurgery over other therapies. However, not all radiosurgical technologies or institutions may have experience in the treatment of the disorders described above. Patients should discuss their own specific situation with their surgeon and radiation oncologist before making any treatment decisions. When properly performed for the right indication, radiosurgery can lead to excellent clinical outcomes that maintain patient quality of life and function.

Dr. Douglas Kondziolka is Professor of Neurological Surgery and Radiation Oncology at the University of Pittsburgh and Co-director of the Center for Image-Guided Neurosurgery. His clinical and research work in radiosurgery was supported by a grant from the National Institutes of Health.

Dr L. Dade Lunsford serves as Professor and Chairman of the Department Of Neurological Surgery at the University of Pittsburgh, Professor of Radiation Oncology and Co-director of the Center for Image-Guided Neurosurgery.

Dr. John C. Flickinger is Professor of Radiation Oncology and Neurosurgery at the University of Pittsburgh.

Correspondence may be addressed to Dr. Douglas Kondziolka, UPMC Presbyterian, University of Pittsburgh Medical Center, Suite B-400, 200 Lothrop Street, Pittsburgh, PA 15213-2582 USA; phone +412-647-6782; or fax +412-647-0989.

> "If at first the idea is not absurd, then there is no hope for it."
> *- Albert Einstein*

Indications for Treatment

Continued from page 10

ing a brain tumor.

◆ Brain tumor and brain disorder research is underfunded and the public, in general, is unaware of the magnitude of the problem.

◆ Brain disorders like Parkinson's, epilepsy and psycho-neuro disorders remain in research phases.

◆ Currently, most brain tumors and brain disorders cannot be prevented because their cause is still unknown.

◆ ***Neurosurgical stereotactic radiosurgery can be utilized to treat brain tumors and brain disorders as either the primary treatment, secondary treatment or an adjunct treatment.***

brain talk

Volume 6, Number 1

The International Radiosurgery Support Association is an independent organization dedicated to providing information through personal contact and educational materials, encouraging research and promoting patient options about radiosurgery treatment and its availability.

- Rebecca L. Emerick
  Managing Director
- Tonya K. Ledbetter
  Editor
- Tomasz Helenowski
  Medical-Technical Advisor
  Chicago, IL USA

Contributing Authors and Medical Advisors:

- Alan Appley
  Orlando, FL USA
- Ronald Brisman
  New York, NY USA
- Lawrence Chin
  Baltimore, MD USA
- Alain C de Lotbinière
  New Haven, CT USA
- Christopher Duma
  Newport Beach, CA USA
- Michael S. Edwards
  Sacramento, CA USA
- Maheep Singh Gaur
  New Delhi, India
- Deane Jacques
  Los Angeles, CA USA
- Jonathan Knisely
  New Haven, CT USA
- Douglas Kondziolka
  Pittsburgh, PA USA
- Edward R. Laws Jr.
  Charlottesville, VA, USA
- Christer Lindquist
  London, England UK
- L. Dade Lunsford
  Pittsburgh, PA USA
- Georg Norén
  Providence, RI USA
- Kenneth Ott
  La Jolla, CA USA
- Swaid N. Swaid
  Birmingham, AL USA
- Robert Timmerman
  Indianapolis, IN USA
- Harish Thakrar
  Chicago, IL USA
- Aizik L. Wolf
  Coral Gables, FL USA
- Ronald Young
  Los Angeles, CA USA

BRAIN TALK (ISSN 1086-427X), IRSA's support publication, is published quarterly by the International Radiosurgery Support Association. Business office located in Harrisburg, PA. Contents copyright 2001 by IRSA. All rights reserved. Call (+717) 671-1701 for subscription information.

Disclaimer

This publication is not intended as a substitute for professional medical advice and does not address specific treatments or conditions specific to any patient. All health and treatment decisions must be made in consultation with your physician(s), utilizing your specific medical information.

International Radiosurgery Support Association

Delivery: 3540 N. Progress, S. 207, Harrisburg, PA 17110 USA
Mailing: P.O. Box 60950, Harrisburg, PA 17106-0950 USA
Phone: +(717) 671-1701 Fax: +(717) 671-1703

PRSRT STD
US Postage
PAID
Harrisburg, PA
Permit No. 917

ADDRESS SERVICE REQUESTED

Internet: www.IRSA.org
Email: getinfo@irsa.org

Understanding Radiosurgery

Continued from page 9

can fractionate treatments over several days, having a flexibility that is not available with other machines. These fractionated treatments are referred to as fractionated stereotactic radiotherapy (FSR) or stereotactic radiotherapy (SRT).

Because of multiple manufacturers with linear accelerator units, data and results are usually not comparable between different units and treating sites, as each type of unit requires different calibrations and adjustments. As a result, there may appear to be a lack of published research available about a diagnosis and treatment.

In general, most LINAC treatment are performed over multiple sessions and without the benefit of a neurosurgeon. There are some highly developed treating centers where neurosurgeons utilize the machine and treat in one-session treatments. However, this is not the rule.

Types of Tumors that are Treated with Radiosurgery and Radiotherapy

Stereotactic radiosurgery may or may not be appropriate for a condition. It may be used as the primary treatment or recommended in addition to other treatments that are needed. Only a treating neurosurgeon who operates radiosurgery equipment can decide whether a person can be treated. A neurosurgeon must always be present during one-session treatment and should work with a radiation oncologist when the brain is being targeted. Some of the most common indications for treatment are:

- Arteriovenous malformations
- All benign brain tumors including:
  Acoustic neuromas
  Meningiomas
  Chordomas
  Hemangioblastomas
  Craniopharyngiomas
  Pineal and pituitary tumors
- All malignant brain tumors including:
  Glial tumors and astrocytomas
  Hemangiopericytomas
  Glomus Tumors
  Chondrosarcomas
  Other Low grade tumors
- Metastatic brain tumors
- Functional disorders:
  Trigeminal neuralgia
  Essential tremors
  Parkinson's tremors and rigidity
  Intractable Pain
  Epilepsy (In multi-institutional trials)
  Psychoneurosis
  Obesity (In research)

Treatment for functional disorders should be limited to one-session radiosurgery machines (usually cobalt^{60}) using a fixed frame that is fastened to the heads with pins.

Other Neurosurgical Instruments

A recent addition to the treatment of tumors that require surgery is intra-operative radiosurgery. After the neurosurgeon has removed most of the tumor, the remaining tumor is treated with the use of a small LINAC with a wand that directs radiation to the residual tumor while the head is open for surgery. The Photoelectron Corporation has recently received approval to sell the INTRABEAM®, to perform intraoperative radiation therapy (IORT). This machine appears to have advantages for the treatment of body cancers like breast and colorectal cancers. While not readily available in treating facilities at this time, initial studies have shown promising results. ∞